



# Laparoscopic Ventral Hernia Repair Using the Carter-Thomason CloseSure<sup>®</sup> System

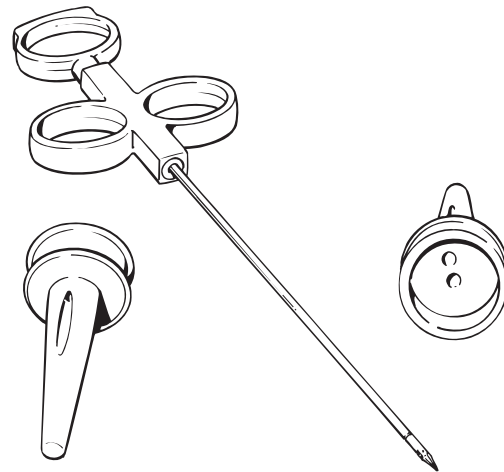
## Introduction

Ventral hernias are one of the most common types of abdominal hernias, with most occurring after a laparotomy. Approximately 90,000 ventral hernia repairs are performed annually in the United States.<sup>1</sup> High recurrence rates reported after open surgical repair have led to the development of new techniques and strategies for hernia repair.<sup>2</sup> With technological advancements in materials and instrumentation, and refinements in operative techniques, a laparoscopic approach to ventral hernia repair has gained increasing acceptance. Laparoscopic technique provides a number of advantages including reduced postoperative pain, a shorter hospital stay, quicker recovery, and improved cosmetic results.<sup>3-5</sup> Large studies have also confirmed lower recurrence rates (<4%)<sup>1</sup> and a lower mesh infection rate.<sup>6</sup>

The basic approach to laparoscopic ventral hernia repair uses prosthetic mesh that overlaps the hernia defect and is tacked in place around the perimeter. Additionally, transabdominal fixation sutures are placed to ensure stable and secure mesh placement. However, laparoscopic technique for ventral hernia repair is not without complications and is still evolving. In particular, the placement of the mesh and transabdominal sutures can be cumbersome.

This paper describes a simple technique to perform laparoscopic ventral hernia repair using the Carter-Thomason CloseSure System (Figure 1).

The system contains a single-use Carter-Thomason<sup>®</sup> suture passer and two Pilot<sup>®</sup> suturing guides to ensure reproducible and controlled suture placement during full-thickness trocar wound closure.

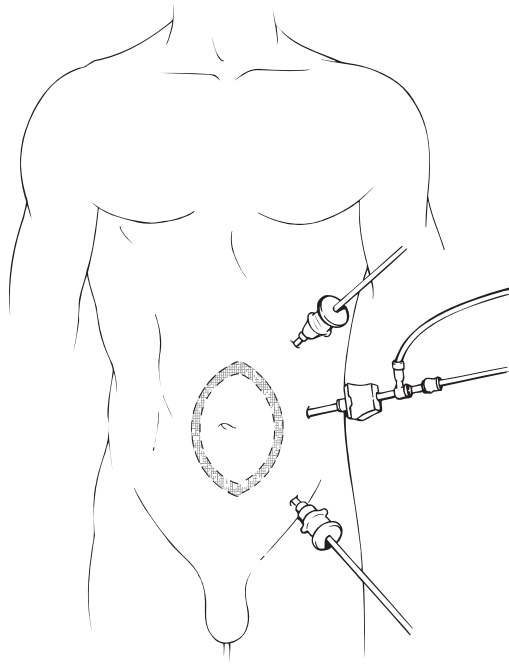


**Figure 1.** Carter-Thomason CloseSure System.

The suture passer is used to place transabdominal fixation sutures and to perform full-thickness trocar wound closure. Franklin<sup>7</sup> previously described the use of the Carter-Thomason suture passer in ventral and incisional hernia repair using a slightly different technique.

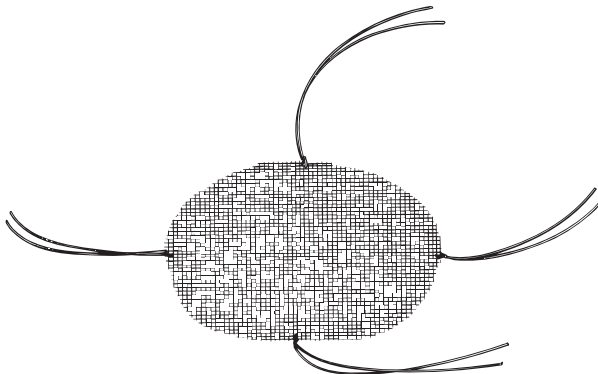
## Operative Technique

The procedure is performed with the patient under general anesthesia. The patient is placed in a supine position. Pneumoperitoneum is established and ports are placed as desired depending on the size and location of the hernia. Laparoscopic ventral hernia repair is usually performed using three ports. Generally, a 10 mm port is used for the laparoscope and mesh introduction, and 5 mm ports are placed on either side of the camera port for instrumentation (Figure 2).



**Figure 2.** Trocar placement for ventral hernia repair.

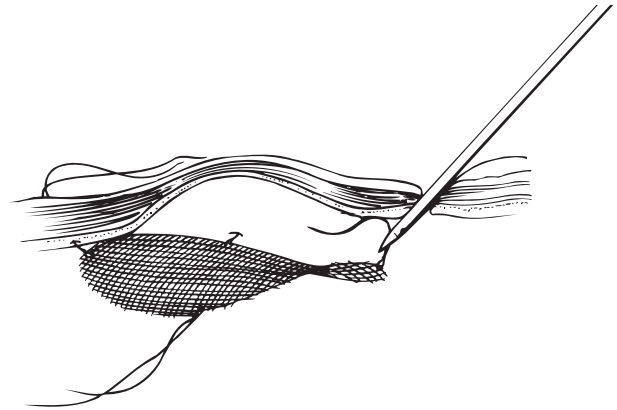
An angled laparoscope is used to facilitate visualization. The abdomen is explored, and the hernia is identified. Adhesiolysis is performed. Hernia sack reduction is performed, and the size of the defect is measured. The mesh is tailored so that it extends approximately 3-5 cm beyond the hernia defect in all dimensions. Marks are made on the mesh and the skin to assist with intra-abdominal orientation. Non-absorbable sutures are tied at the edge of the mesh in four equidistant locations, leaving approximately 15 cm tails (Figure 3).



**Figure 3.** Placement of pre-tied sutures.

The mesh is rolled around a laparoscopic grasper, introduced through a 10 mm trocar, and then unrolled.

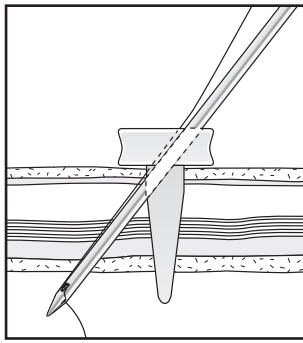
- A small 2 cm incision is then made in the abdominal wall corresponding to placement of one of the pre-tied sutures, and the Carter-Thomason® suture passer is pushed through the incision at an angle to ensure capturing the fascia. One tail of the suture is picked up with the Carter-Thomason suture passer and pulled out through the skin. The suture passer is then placed back through the same incision, but at an opposite angle in order to grasp the fascia on the opposite side. The other suture tail is then pulled out through the skin (Figure 4).



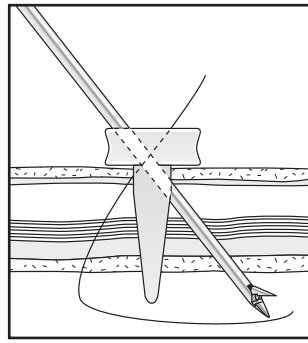
**Figure 4.** Mesh fixation using pre-tied sutures and the Carter-Thomason suture passer.

The process is repeated with the remaining three sutures. After all four sutures have been pulled out through the skin, the sutures are pulled to bring the mesh into contact with the abdominal wall. The sutures are then tied, and the knots are buried subcutaneously.

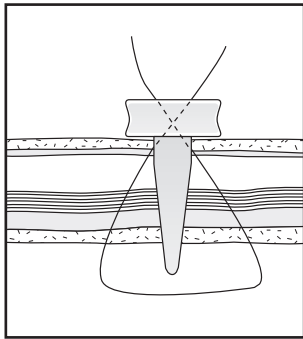
Tacks are then placed around the perimeter of the mesh. All of the port sites are closed using the Carter-Thomason suture passer and the Pilot® guides (5 mm and 10-12 mm) included in the system using the technique as described by Elashry, et al.8 (Figure 5).



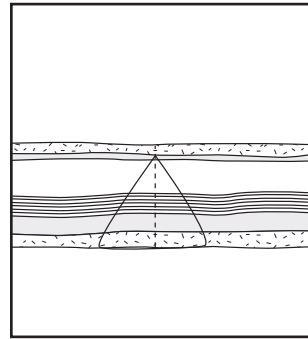
1. Insert the Pilot guide with the holes aligned cephalad to caudad. Use the suture passer to push suture through the Pilot guide and the peritoneum. Drop the suture and remove the suture passer.



2. Push the suture passer through the opposite side of the Pilot guide and pick up the suture.



3. Pull the suture up through the peritoneum, muscle, fascia and guide.



4. Remove the Pilot guide and tie.

**Figure 5.** Full-thickness trocar wound closure with the Carter-Thomason CloseSure® System.

To conclude the hernia repair, the skin incisions are then closed.

## Discussion

Ventral hernia is a common complication of abdominal surgery. Laparoscopic repair is establishing itself as the treatment of choice for hernia repair because of the benefits it offers compared to an open approach. These include reduced postoperative pain, a shorter hospital stay, quicker recovery, improved cosmetic results and lower recurrence and mesh infection rates.

The basic technique uses synthetic mesh that overlaps the hernia defect for a tension-free repair. However, the specifics of laparoscopic ventral hernia

repair are evolving based on the results of long-term studies and the refinement of instrumentation and materials. The use of transabdominal fixation sutures in addition to the placement of tacks around the perimeter of the mesh is key to the lower recurrence rate observed with laparoscopic ventral hernia repair.<sup>9</sup> The Carter-Thomason suture passer included in the Carter-Thomason CloseSure System helps ensure a fast, simple and convenient method of placing full-thickness transabdominal sutures.

While laparoscopic ventral hernia repair offers many benefits, the technique is also associated with new types of complications. Herniation into the trocar site is one of these surgical complications and represents a potentially dangerous cause of post-operative morbidity and mortality. A Richter's hernia may develop if a loop of bowel protrudes through the defect and becomes strangulated. The incidence of port-site herniation in the general population has been reported at .23% to 3.1%<sup>10</sup> and is higher in obese and bariatric patients.<sup>11</sup> This complication can be prevented through full-thickness closure of all port sites. The Carter-Thomason CloseSure System has proven 100% effective in achieving such closure in a fast and reliable manner.<sup>8</sup>

In summary, the Carter-Thomason CloseSure System facilitates laparoscopic ventral hernia repair and offers physicians a number of benefits in placing and securing the mesh and in preventing port-site herniation through full-thickness trocar wound closure.

## References

- <sup>1</sup> Thoman DS, Phillips EH. Current status of laparoscopic ventral hernia repair. *Surg Endosc* 2002;16:939-942.
- <sup>2</sup> Liberman MA, Rosenthal RJ, Phillips EH. Laparoscopic ventral and incisional mesh repair: a simplified method of mesh placement. *J Am Coll Surg* 2002;194:93-95.
- <sup>3</sup> Ramshaw BJ, Esartia P, Schwab J, et al. Comparison of laparoscopic and open ventral herniorrhaphy. *Am Surg* 1999;65:827-831; discussion 831-832.
- <sup>4</sup> Heniford BT, Park A, Ramshaw BJ. Laparoscopic ventral and incisional hernia repair in 407 patients. *J Am Coll Surg* 2000;190:645-650.
- <sup>5</sup> Verbo A, Petito L, Pedretti G, et al. Use of a new type of PTFE mesh in laparoscopic incisional hernia repair: the continuing evolution of technique and surgical expertise. *Int Surg* 2004;89:27-31.
- <sup>6</sup> Moon V, Chaudry GA, Choy C, et al. Mesh infection in the era of laparoscopy. *J Laparoendosc Adv Surg Tech A* 2004;14:349-352.
- <sup>7</sup> Franklin ME, Dorman JP, Glass JL. Laparoscopic ventral and incisional hernia repair. *Surg Laparosc Endosc* 1998;8:294-299.
- <sup>8</sup> Elashry OM, Nakada SY, Wolf JS Jr, et al. Comparative clinical study of port-closure techniques following laparoscopic surgery. *J Am Coll Surg* 1996;183:335-344.
- <sup>9</sup> Cobb WS, Kercher KW, Heniford BT. Laparoscopic repair of incisional hernias. *Surg Clin N Am* 2005;85:91-103.
- <sup>10</sup> Kadar N, Reich H, Liu CY, et al. Incisional hernias after major laparoscopic gynecological procedures. *Am J Obstet Gynecol* 1993;168:1493-1495.
- <sup>11</sup> Bonatti H, Hoeller E, Kirchmayr W, et al. Ventral hernia repair in bariatric surgery. *Obes Surg* 2004;14:655-658.



[www.coopersurgical.com](http://www.coopersurgical.com)

95 Corporate Drive, Trumbull, CT 06611  
800.243.2974 • 203.601.5200  
International:  
203.601.9818 • fax 203.601.4747